



# Orthopaedic surgery

## OSTEOARTHRITIS OF THE HIP JOINT

Osteoarthritis is the most common disease of the hip joint. This means an age related wear of the cartilage. However other diseases like rheumatoid arthritis, malformation like congenital dislocation or osteonecrosis may end up in osteoarthritis. The patients suffer from increasing pain in the groin, around the area of the greater trochanter and of the thigh. Usually the pain is accompanied by some stiffness due to muscular contractures. The x-rays show a narrow joint line and osteophytes (bony appositions) at the acetabulum and around the femoral head. In many cases osteoarthritis is very painful and does not respond very well to conservative treatment, therefore the implantation of an artificial hip joint is the only solution. Similar to the natural hip joint the prosthesis has an acetabulum (cup), a ball-head, neck and shaft. Today cementless fixation is the method of choice whereas cement fixation of some components may be restricted only to revision surgery. In our hospital a threaded titanium cup is combined with a polyethylene inlay, which articulates with a ceramic ball-head. The head again is fixed onto a titanium stem. This stem is brought into the femoral shaft "press-fit" in a separate step. Sometimes – mainly in younger patients – a metal ball-head is combined with a metal gliding surface of the cup. In order to restore a natural biomechanical function the procedure is planned accurately with x-rays, transparent templates and tracing paper. This gives the surgeon a precise idea of the implant sizes to choose.

### Cementless prosthesis

Our modern implants, which stand the test of time since 1984 have a special titanium surface. Bone "loves" titanium and after rigid "press-fit" fixation it is firmly growing onto these surfaces. In the early years after cementless fixation was introduced, these new implants were restricted to very young patients. Later on the indication was gradually enlarged and today it is the method of choice for almost all patients regardless of their age.

### Cemented prosthesis

If the bony condition of the patient's hip joint is so critical that a primary stable fixation of the implant may be difficult or even impossible to achieve, the total prosthesis is plugged in by the help of bone cement. This gives immediate stability and is still a reliable procedure. With modern cementing techniques the survival time of the implant is normally longer than 10 years, whereas cementless fixation may last much longer.

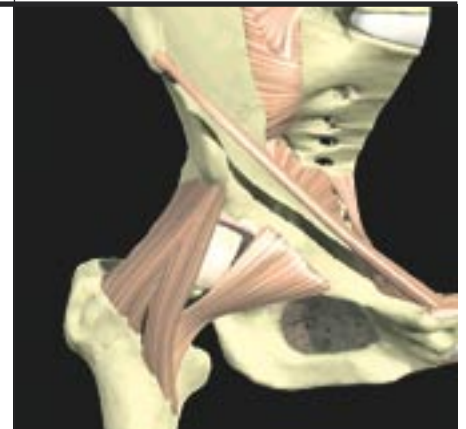
### Hybrid-prosthesis

This means a combination of cementless and cemented components. Routinely the cup is threaded or fixed in "press-fit" technique, whereas the stem is cemented. Again there are diffe-

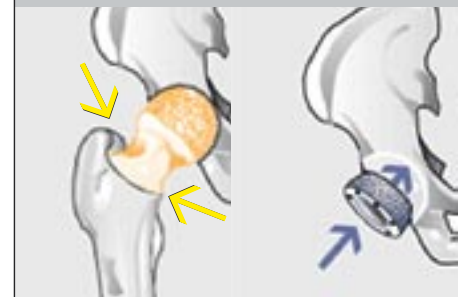
rent materials like ceramic, polyethylene or metal, which can be combined as gliding partners like femoral head and inner surface of the cup.

### Rehabilitation

The hospital stay lasts between 1 and 2 weeks. The patients are allowed to walk with full weight bearing from the very first day with the help of two crutches or a walker and the assistance of a therapist. The affected extremity is repeatedly placed on a continuous passive motion machine every day. Later on early functioned treatment is followed by intensive strengthening program for all the pelvitrochanteric muscles and the thigh. After wound healing aqua treatment will start and the patient will be off his crutches after 6 to 8 weeks. In our hospital the discharged patients are referred directly to some very specialized rehabilitation centers where they stay between 2 and 4 weeks. Afterwards the patients should continue to see their therapists 3 times weekly over 2 to 3 months. After routine procedures and an uneventful postoperative course and normal rehabilitation sports like swimming, golf, bicycling or cross country skiing are possible. Because of the risks of periprosthetic fractures we are not recommending alpine skiing after total hip joint replacement, but there are always some passionate experts who cannot resist!

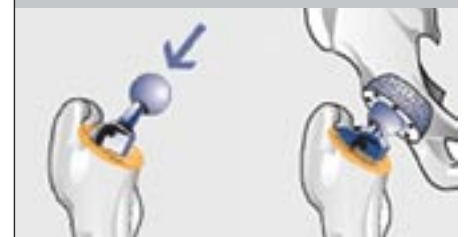

right hip joint with femoral head and ligaments (anterior aspect)

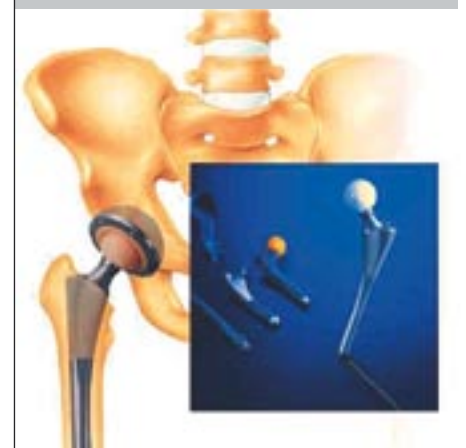


surgical steps:

1. resection of the femoral head
2. reaming of the acetabulum and implantation of the cup



3. fixation of the stem into the femoral shaft
4. reduction of the new hip joint



example of an artificial total hip joint different types of prostheses (small frame)