



Orthopaedic surgery

SHOULDER JOINT

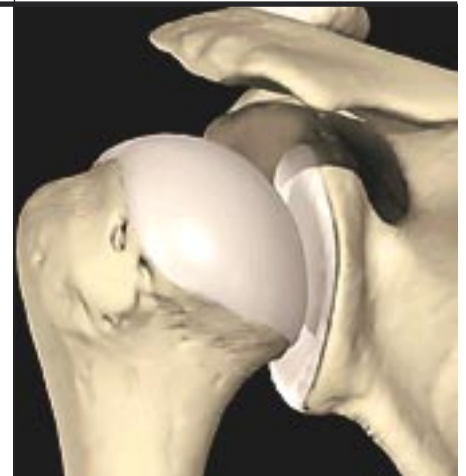For the treatment of the shoulder joint immense progress has been achieved over the last years. This is mainly due to the introduction of minimal invasive surgery. The development of precise instruments, new resorbable suture material and fixation systems were essential. Through tiny little skin incisions the shoulder joint can be operated on by avoiding major surgical trauma similar to the knee or elbow joint. By the help of a thin lens, which is connected to a chip camera and a monitor, the inner space of the joint can be completely inspected. Painful shoulders, limited range of movement, shoulder instabilities, calcification or small tears of the rotator cuff can be treated very effectively with these techniques. Postoperative pain is low and functional treatment can be started at the very first day. Scars are barely visible. Most interventions can be made on an outpatient basis or as daycases. Endoscopic minimal invasive surgery is very demanding and needs a lot of skill and experience of the surgeon. A modern sophisticated instrumentation is very important.

Anatomy

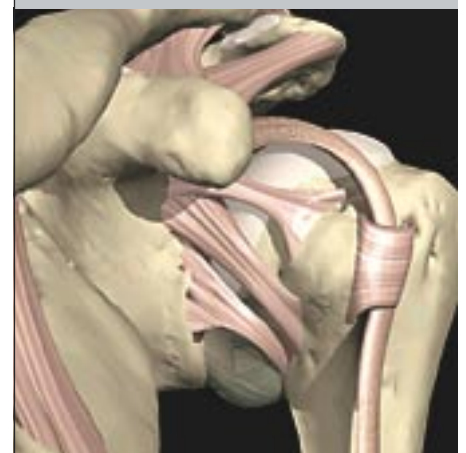The free range of motion of the whole arm is mainly related to the great mobility of the shoulder joint with its large humeral head and the relatively small glenoid. The shoulder joint has the greatest range of movement of all joints of the human body. Since the congruence between humeral head and the cavity of the glenoid is minimal, a complicated system of ligaments and tendons, labrum and joint capsule is necessary for the stabilization of the joint. The dislocation of the humeral head, which is a very common injury, is always associated with injuries to these structures and may lead to chronic instability and recurrent dislocation of the shoulder joint.

A group of muscles, the so-called rotator cuff, is separating the shoulder joint from a gliding area (subacromial space) below the "roof" of the shoulder, the acromion. The rotator cuff is very important for the centering of the humeral head and for elevation and rotation of the arm. There is a bursa between the acromion and the rotator cuff which facilitates the gliding of the cuff. Tears of the rotator cuff, degeneration of their

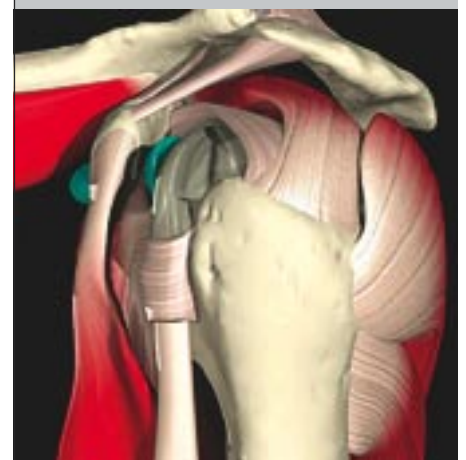
tendons, bony appositions at the acromion, osteoarthritis of the articular connection between clavicle and acromion (acromioclavicular joint) or calcified deposits in the rotator cuff often are causing a painful inflammation of the subacromial bursa. The patient's history, a thorough clinical examination and x-rays as well as ultrasound and/or MRI will lead to a precise diagnosis.



*humeral head and glenoid
left shoulder (rear view)*



*Ligamentous structures and long head of biceps
tendon - left shoulder (front view)*



*tendons and muscles of the rotator cuff - left
shoulder (side view)*