



# Orthopaedic surgery

## ROTATOR CUFF

The tendons of 4 muscles, connecting the scapula with the humeral head, are the so called rotator cuff. These tendons are rather wide and tightly connected to each other, thus forming a cuff, which secures the humeral head. The intact rotator cuff is not only the main stabilizer of the shoulder joint but also very important for the transmission of rotational forces and the mobility of the arm in general.

### Rotator cuff tear (acute/chronic)

Chronic degeneration is the most frequent cause for lesions of the rotator cuff. These lesions are increasing with age. Commonly the onset of symptoms is caused by minor injuries. Not seldom the rotator cuff is hurt after a shoulder dislocation. The most affected tendon of the cuff is the supraspinatus tendon. The patients feel the rupture as an acute pain, while the arm becomes suddenly very weak and is almost impossible to raise again (pseudoparalysis). The tear is followed by chronic pain, especially during the night. In young patients or patients with highly demanding sports activities, operative treatment is indicated. For aged patients surgery may be needed after an unsatisfactory conservative treatment of min. 3 months. If the tear is associated with a frozen shoulder this should be treated prior to reconstructive surgery of the rotator cuff.

### Operative technique

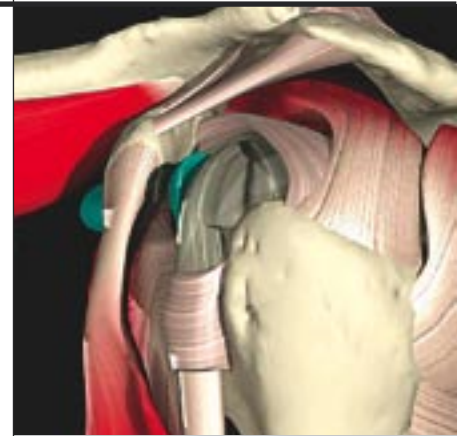
The goal of the operation is to reattach the ruptured tendon at the humeral head to restore normal load transmission. At the same time inflamed tissue and osteophytes must be removed. Small rotator cuff tears can be treated by the means of arthroscopy but in the majority of cases open surgery is needed. Through a short skin incision the torn tendons are exposed and fixed with special anchors. This procedure is routinely combined with a subacromial decompression (acromioplasty).

### Long head of biceps tendon/LBS (rupture, degeneration)

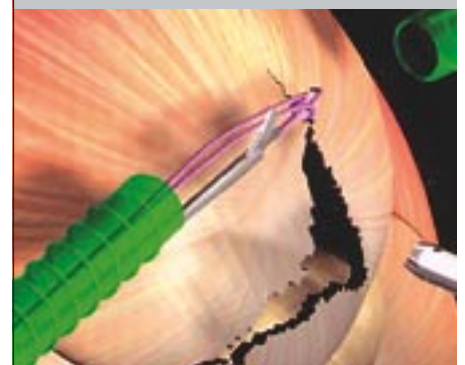
Together with other muscles the LBS is transmitting forces during anterior elevation of the arm. Its anatomical course is rather complicated and lesions or inflammatory reactions of the tendon are frequent. Quite common is the posttraumatic lesion of the insertion of the tendon at the upper rim of the glenoid (so called SLAP lesions). This may need refixation of the tendon under arthroscopic control. In cases of chronic inflammation and partial degenerative tears, a complete tenotomy can be helpful.

### Rehabilitation

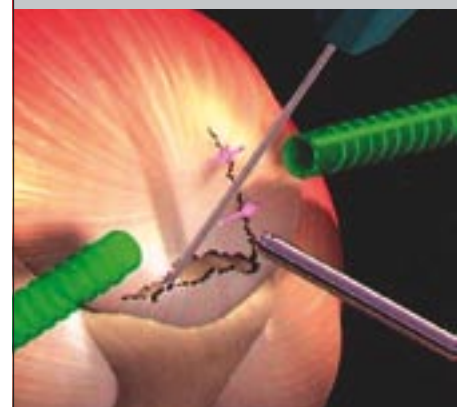
In order to minimize the postoperative inflammatory reaction the shoulder is immobilized for only a few days. This is followed by a rather long period of rehabilitation (3 to 6 months). Early passive and active assisted exercises are important to avoid adhesions. Overhead activities should be avoided for 6 to 8 weeks. The overall prognosis is good.



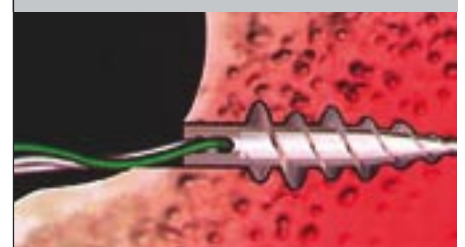
Muskeln und Sehnmuskles und tendons of the rotator cuff - left shoulder (side view)  
en der Rotatorenmanschette linke Schulter (seitliche Ansicht)



rotator cuff tear, longitudinal and transversal tear of supraspinatus tendon



reconstruction of rotator cuff tear



fixation of the torn tendon at the bony insertion of the humeral head with suture anchor